Rishi Kumar

Ultrasound Notes

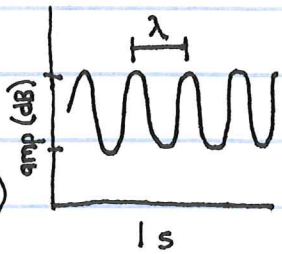

diagnostic U/S: 1-20 MHz → reflect, absorb, transmit, scatter

frequency ('f'): waves/second (in Hz) wavelength ('λ'): distance b/w waves

amplitude (dB loudness): wave height velocity ('$\vec{v}$'): $\lambda \cdot f$ (1540 m/s soft tissue)

f ∝ sound source <u>only</u> ↑λ, ↓f, ↑depth, ↓resolution (differentiating two objects)

resolution: axial (structures parallel to beam); ↑ w/ ↑f probe

(no greater than 1-2 λ) lateral (structures ⊥ to beam); ↑ w/ ↑f probe, adjusting <u>focal zone</u>, minimizing gain

temporal (moving structures) ∝ frame rate; ↑FR by ↓ depth and narrowing image sector

FR: images captured in a second (Hz)

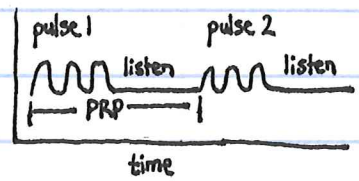

pulse repetition period (PRP): time b/w start of one pulse to the next

" frequency (PRF): pulses/second, <u>only</u> ∝ imaging depth (<u>not</u> f)

As depth ↑, PRP ↑, PRF ↓

Bioeffects: thermal (↑ temp due to U/S absorbance, eye sensitive, more w/ CWD and CFD)

cavitation: vibrate small gas bubbles (if ↑ mechanical index → bubbles burst + damage cells)

M-mode: one slice (~1800 Hz) over time $f_{shift} = F_R - F_T = \frac{2 \cdot F_T \cdot \vec{v} \cdot \cos(\theta)}{c}$

Doppler effect: Δ in f due to motion b/w source and receiver (↑v = ↑ Doppler shifts)

+ shift if objects approach each other, − if away (w/ regards to x-axis)

spectral: <u>PWD</u> (desire ↑PRF so ↓ depth, not good if $\vec{v} > 2$ m/s; range specific, low $\vec{v}$, choose sampling gate) vs. <u>CWD</u> (all $\vec{v}$ along beam, high $\vec{v}$ measurable)

<u>aliasing</u>: to determine U/S ≈ f, it must be sampled <u>twice</u>/λ, so maximum f_{shift} is ½ PRF

<u>CFD</u>: based on PWD (each pixel a PWD sample/result), θ ! 0° or 180° limit CFD, subject to aliasing too

<u>variance map</u>: blue (away), green (turbulent away), red (toward), yellow (turbulent toward)

<u>tissue doppler</u>: listens to high amplitude, low velocity waves (LV diastology e', a'; RV systolic fxn s')

PWD: listens to fast and quiet (laminar blood), TDI listens to slow and loud (muscle)

<u>compression</u>: molecules squeezed by U/S: ↑ surrounding pressure

<u>rarefraction</u>: molecules move away: ↓ pressure, can create vacuum, <u>cavitation</u> refers to these vacuums

created by expanding/shrinking bubbles: <u>mechanical index</u> (∝ cavitation) ↑ during peak rarefraction pressure (most negative pressure)

$$MI = \frac{\text{peak rarefraction P}}{\sqrt{f}}$$

velocity-time integral (VTI): displacement of an RBC, useful for CO calculation: $SV = \pi r^2_{LVOT} \cdot VTI_{LVOT}$ requires sinus error w/ angle on LVOT and diameter

$Q_p : Q_s = \frac{CSA_{PA} \cdot VTI_{Pa}}{CSA_{LVOT} \cdot VTI_{LVOT}}$ $\Delta P = 4v^2$ (simplified Bernoulli)

continuity: ~~$CSA_1 \cdot LV$~~ $CSA_1 \cdot VTI_1 = CSA_2 \cdot VTI_2$

IVC inspiration: ↓ RA and pleural P → ↑v_{IVC}, ↓ IVC diameter (opposite for expiration)

echo contrast: enhance doppler, PFO/shunts, highlight endocardium, embolization in TCD, intrapulm shunt in liver pts

RH: agitated saline; LH: high MW gas in albumin or phospholipid

CI: <6 y/o, pregnant, allergy

reverberation artifact: equal distance b/w lines, ↓ intensity w/ ↑ distance, lack of independent motion (comets, mirror image)

beam width artifact: 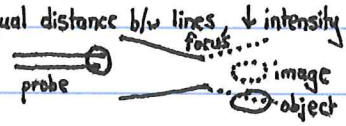

near field clutter: many NF reflections: optimize TGC, focus, depth, use contrast/harmonics

TTE windows: suprasternal notch (1 o'clock), parasternal, apical, subcostal (L shoulder); A2C (LV, LA, MV) rotate 60° CCW A4C; A3C (LA, MV, LV, LVOT, AV, A_o) rotate 120° CCW A4C

transducer manipulations: tilting, rotating, sliding, rocking, angling 

harmonic imaging: f from tissues instead of fundamental f → 2nd harmonic is $2f_{fundamental}$

overall gain: Δ amplification of returning echo; TGC: selective amplification in horizontal bands

sector size: ↑ FR w/ ↓ depth and sector size

LV systolic fxn

Δ in LV shape/size over cardiac cycle: global vs. regional, quantitative vs. qualitative

linear: fractional shortening (FS): PSLA or PSSA: $FS(\%) = \frac{LVEDD - LVESD}{LVEDD} \times 100$ normal ≥ 30%, severely ↓ < 20%

MAPSE: MV apical mvmt due to longitudinal fibers: ≥11 (men), ≥13 (women) ~ LVEF ≥ 55%

E point septal separation: ALMV almost touches IVS in early diastole, EPSS > 7 mm ∴ LVEF < 30%

all linear techniques limited by RWMAs, arrhythmias, and off-axis

2D: fractional area change (FAC) $= 100 \times \frac{LVEDA - LVESA}{LVEDA}$ 35-65% normal

3D: volume measurements: Simpson's in A4C/A2C - summation of discs along long LV axis: $vol = \sum \pi r^2 h$

$LVEF\ (normal > 55\%) = \frac{LVEDV - LVESV}{LVEDV}$

wall thickness: 

measure at MV leaflet tips at end diastole w/ M-mode

qualitative: do walls thicken? MV annulus movement? ALMV touch septum? → hyper, normal, mild, mod, severe

LV strain: Δ length within certain direction relative to baseline length : global longitudinal strain (GLS) in terms of myocardial length (mL) in systole (s) and diastole (d): $GLS\ (\%) = \frac{mL_s - mL_d}{mL_d}$

normal GLS is ~20% or more negative

piffalls : endocardial dropout, foreshortening

LV diastology

diastolic dsg dysfxn : abnl LV relaxation and stiffness → ↑ LV filling pressure

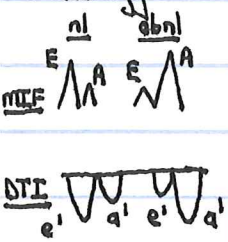

① LV relaxation normal ? → no WMA, normal LVEF, E > A, LA volume normal (can be ↑ in athletes, AFib, ↑CO)

abnormal → ↓EF, WMA, concentric LVH (ok in athletes), ↓e', ↑LA volume (sensitive but not specific)

E/A < 0.8 , lat e' < 8, septal e' < 7 cm/s

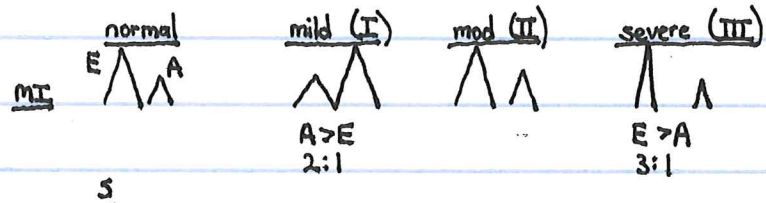

RV physiology

crescent: inflow, outflow, trabeculated apex

1° longitudinal shortening, large free wall

normally < 2/3 LV size

RV wall thickness (nl 3±1 mm): ↑ thickness ∝ chronic ↑ pressure, pHTN, infiltrative dz

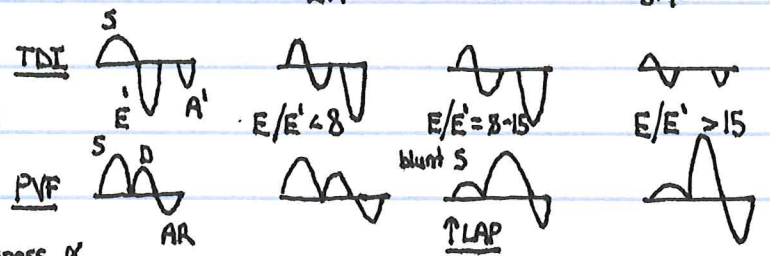

TAPSE: longitudinal motion (<17 mm → dysfxn) $FAC = \frac{EDA - ESA}{EDA} \times 100\%$, < 35% = dysfxn

TDI : RV dysfxn if S' < 9.5 cm/s

RAP : 0-5 mmHg (IVC ≤ 21 mm, >50% sniff collapse); 5-10 (IVC and sniff diverge); >10 (IVC > 21 mm, no sniff collapse)

IVC on ventilator: largest at end inspiration, collapsibility does not ∝ w/ RAP; ≤12 mm 100% specific for RAP < 10

E/E' > 4.7 ∴ RAP ≥ 10 mmHg $RVSP = \Delta P_{RV-RA} + RAP = 4(V_{TR})^2 + RAP$ → normal $\begin{cases} \leq 35 \text{ mmHg} \\ V_{TR} < 2.9 \text{ m/s} \end{cases}$

chronic RV dysfxn: LV failure, pHTN, OSA, valvulopathy → RA dilation, RVH

ARDS → ↑PEEP/intrathoracic P → ↑RAP; ↓P_{O_2} will ↑PVR → RV strain

post-op RV dysfxn: SVT, preexisting RV dysfxn, air to RCA, CPB > 150 m, 11% rate after LVAD

Hemodynamics

PASP = $4(V_{TR})^2 + RAP$ (if no PS) ; PADP = $4(V_{PI})^2 + RAP$ (b/c RAP = RVEDP); IVC ↑ in RLD position, ↓ " LLD "

spon: diameter/collapse ∴ CVP

IVC caveats: pregnancy, abd. compartment ; vented: " ∴ fluid responsiveness

athletes have dilated, collapsible IVC (esp. swimmers)

hepatic vein flow (HVF) : diameter 0.8 ±0.2 cm normally

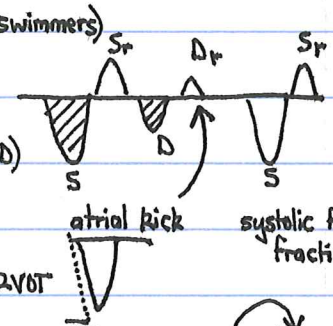

systolic forward flow (S), brief reversal (S_r), diastolic flow (D)

diastolic reversal w/ atrial systole (D_r)

systolic filling fraction $= \frac{VTI_S - \cancel{VTI_{Dr}}}{(VTI_S + VTI_D)}$

mPAP = 80 − (0.5× AT) where AT = acceleration time PWD RVOT

LAP normal if E/e' < 8 (↑ if E/e' > 14) ; E load-dep., e' indep., LAP ∝ PAOP (not related to fluid responsiveness)

E/e' not accurate : MS, heavy MAC, prosthetic MV, mod/severe MR, normal LVEF/diastology

typically $e'_{septal} < e'_{lat}$, use average or septal e'

Preload Responsiveness CVP, E/e', LV end diastolic area (or volume) are all ∝ preload (not responsiveness)

dynamic measures Δ preload + observe Δ in CO

SVV limitations: spontaneous breaths, tachypneic, arrhythmia , low V_T, open chest, ↑IAP, RH failure ↑IAP, severe TR/RV dysfxn

normal inspiration : IVC ↓, SVC ↑ (opposite during PPV) ; limitations: spontaneous, hyperinflation, tamponade

10 s, 50 cc IVF challenge and PLR great options , end-expiratory occlusion in PPV too

Lung U/S → PTX

① lung sliding b/w visceral/parietal pleura → M-mode w/ "sandy beach" below pleura and "waves" above

+ lung sliding r/o PTX (NPV ~ 100%) ; − sliding also in atelectasis, ARDS, contusions

② lung pulse → shivering of lung from cardiac pulsations r/o PTX → regular disturbances from pleural line

if emanating from superficial structures, cannot exclude PTX ; dyspnea can cause

muscle/fascial sliding causing artifacts

③ B lines → from visceral pleura due to fluid → "comet tails" extending to bottom screen >3 in rib space abnl

subQ emphysema causes artifacts from chest wall ; even 1 B-line excludes PTX

④ lung point → transitional point where PTX begins, one side has sliding/pulse and other doesn't

absent if PTX causes complete collapse

A-lines : not real structures, disappear w/ B-lines, occur in normal lung and PTX, often at twice

the pleural depth (double reflected waves)

fluid nature : <u>simple</u> effusion (transudate, anechoic); <u>complex</u> (exudative, echoic) → homogeneous: heme, empyema / hetero : ↑ cells (? cancer)

volume est (mL) = 16 × D (mm)

<u>B-lines</u> ∝ dz severity, appear early (before Δ in P/F), represents ↑ lung density

affected by gravity/hydrostatic forces, very <u>sensitive</u> but lack specificity

<u>consolidation</u> : ↓ air/tissue ratio (hepatization), dynamic air bronchograms, irregular borders

↑ EVLW : HF, HD, ARDS, HAPE, etc.

<u>diaphragm dysfxn</u> : thickening fraction (TF) = $\frac{\text{thickness}_{\text{peak insp.}} - \text{thick}_{\text{end exp}}}{\text{thick}_{\text{end exp}}}$

Pericardial Dz

anatomy : fibrous outer (fused w/ parietal) ; serous inner (visceral layer of epicardium) , < 50 cc fluid
parietal fused w/ fibrous

<u>transverse sinus</u> (b/w aorta and mPA) ; <u>oblique sinus</u> (ostium of PV)

effusion : ant to desc. Ao (pleural effusion posterior) : evaluate size, location, composition, hemodynamic fx

<u>end diastole</u> : < 10 mm (50-100 cc), 10-20 mm (100-500 cc), > 20 mm (> 500 cc)

<u>mimics</u> fat pad, hematoma, LV pseudoaneurysm, cyst

<u>fat pad</u> has planes, moves w/ heart, not circumferential (normally AV groove and alongside coronaries)

<u>fibrous</u> (parietal) layer limits chamber distension, influences diastolic ventricular compliance and <u>interdependence</u>

<u>tamponade</u> : ↑ fluid → ↑ pressure → chamber compression → ↓ diastolic filling (loss of 'y' descent in RAP)

↓ CO → ↓ perfusion → brady/arrest

respirophasic competitive ventricular filling :



echo findings : ↑ IVC/hep. veins, effusion, Δ transvalvular flow $\vec{v}$, septal bounce, chamber collapse

sensitive — <u>RA</u> collapse in <u>late</u> diastole (RAP lowest) → early sign of ↑ pericardial P → longer collapse = worse tamponade

specific — RV " early diastole (100% PPV) → may not occur if RV pressure ↑ (ie pHTN)

E wave variation : ≥ 30% MV, ≥ 60% TV ; respirophasic Δ opposite w/ PPV (↑ MV E wave in inspiration)

<u>focal tamponade</u> post CTS usually < 24 hrs or > 5-7 d → loculated coagulum/hematoma

<u>pericardiocentesis</u> w/ echo : CI : INR > 1.5, thrombocytopenic, severe pHTN ; mostly <u>para-apical</u> (> 60%) w/ agit. saline

constrictive pericarditis — thick, inflamed, calcified pericardium → diastolic HF, restricted filling, ↑ intracardiac P

CP ↓ often cured w/ pericardiectomy

MCC: post CTS, pericarditis, idiopathic, radiation, CVD, infn, autoimmune

echo findings: thick, tethered pericardium ± effusion, restrictive TV/MV filling, variation of inflow $\vec{v}$, ↑ IVC

IVS shift, mitral septal e' (preserved) > lateral e' (reduced) (annulus reversus) on TDI, exp. diastolic reversal in HVF

E > A (unlike tamponade), ↑ filling P and normal E/e' pathognomonic for CP (annulus paradoxus)

prominent 'x' and 'y' descents (blunted 'y' in tamponade)

restrictive CM ↓ often need OHT

CP and RCM both ↓ diastolic filling, S/sx HFpEF, RV failure

RCM: idiopathic, amyloid, radiation, fibrosis, sarcoid, hemachromatosis, scleroderma → myocardial process

mitral septal e' ↑ in CP, ↓ RCM, ↑ transmitral $\vec{v}$ variation in CP (nl in RCM), IVS ↑ shift in CP (nl in RCM); ↓ forward HVF and exp. diastolic reversal in CP, ↑ for. flow + insp. dias. reversal in RCM

Shock — MCC is sepsis; hypovolemia (IVF, blood), LV failure (inotrope, revasc., MCS), RV failure (tPA, pressor, MCS) vasomotor tone (pressor, source control, steroids)

r/o emergencies: tamponade (early diastolic RV / late diastolic RA collapse, reciprocal RH and LH Δs during respiration, clinical dx); tension PTX (100% r/o by sliding, 100% ruled in w/ lung point), masses, A_o dissection

hypovolemia (small, hyperdynamic LV, ↓ IVC, preload responsive (if PPV) if SVC collapsibility > 36%, IVC distensability > 12-18%, and resp. variation in A_o $\vec{v}$ > 12-18%; if no PPV, > 12.5% ↑ in LVOT VTI w/ PLR

LV failure: qualitative, FAC, Simpsons, TDI, LVOT VTI, MAPSE → RWMA (CAD, stress, sepsis, myocarditis) vs. global dysfxn (CM, sepsis, intoxication); LV dilation suggests chronic process

RV failure: acute cor pulmonale (sudden ↑ in RV afterload), acute-on-chronic, infarct

valvular: severe regurg/stenosis, masses on leaflets, dynamic LVOT obstruction

vasomotor tone: "distributive", r/o other shock; MCC sepsis/SIRS, neurogenic, anaphylactic adrenal crisis, ESLD

look for big changes: IVC collapsibility <50% to >50%; E/e' (assume normal EF) <8 to 9-14 to >14, PASP from <40 to 40-60 to >60 mmHg

Cardiac Arrest

PEA (electromechanical dissociation, 5 H's and T's); pseudo-PEA (cardiac activity w/o palpable pulse) from tamponade, PE, ↓↓ LVEF, hypovolemia ; cardiac activity ∝ ↑ ROSC

U/S < 10 s (save images) during pulse/rhythm check

Ischemic Dz

6-6-4-1 LV breakdown (basal-mid-apical-cap); "posterior" = "inferolateral"

wall motion score index (WMSI): normokinesis (1, 5 mm, 40% WT), hypokinesis (2, 2-4 mm, <40%) akinesis (3, 0-1 mm, <10% WT), dyskinetic (4, akinetic w/ systolic expansio) , normal WMSI = 1

absence of RWMA ! exclude CAD → stunned and hibernating myocardium

hinge point: abrupt regional dysfxn; tethering: impact by adjacent region

acute aortic syndromes : type A dissection (~1%/hr mortality → surgery), type B (~8% at 1 month, ↓BP+HR so ↓ dP/dt, endovasc. repair); intramural hematoma (ruptured vasa vasorum → within medial wall extending to adventitia), most in DTA in elderly, ↑lipids, atherosclerosis, crescent shaped, high intensity on non-con CT

acute PE : 60/60 sign (acute PAH < 60, RVOT at < 60 ms), McConnell's sign, D-shaped IVS

acute pericarditis : often normal echo, small effusion, dark/thick pericardium, diffuse STE on EKG

~10% 1-4 d post-infarct (∝ size of infarct), Dressler's (1-8 wks) → autoimmune response to necrosis

RWMA w/ normal coronaries : basal inferior/IVS, dilated CM (EF <40%), stress CM, post SAH/ICH, sarcoid, LBBB

Takatsubo CM : acute, transient, LV dysfxn, post-menopausal women after stress, apical ballooning

post-MI cx: shock, mid VSD, ischemic MR, free wall rupture, effusion, LV thrombus (use color → should respect thrombus)

post infarct true ~~aneyrs~~ aneurysm : apical most common, 6x mortality, rupture rare

pseudoaneurysm : 2nd cause mortality (after shock) → lateral wall, pericardium contains rupture (tamponade) "narrow neck", acute angle, saccular, to-and-fro on CFD

post-infarct VSD : murmur 1-7 d, simple (typ. anterior, single tear through) vs. complex (typ. inferior, looks like TR, multiple holes in necrotic IVS); RVSP = SBP − $4V_{VSD}^2$, Q_p/Q_s ~ severity

acute RV infarction : ↓ RVEF, RV dilation, RA → LA shunt via PFO, ↓ TAPSE, s', and IVS motion

U/S in trauma

r/o intra-abd. hemorrhage in <u>blunt</u> trauma : E-FAST (adds lung U/S to r/o PTX)

hepatorenal space (Morrison's pouch), splenorenal view (fluid above spleen), bladder (probe to R, fluid b/w bladder and rectum/uterus), subxiphoid (pericardial blood, fat pad, L hemothorax)

FAST in <u>penetrating</u> trauma → eval PTX and pericardium, if FAST + to OR, if - cannot r/o anything

FAST is cheap, fast, reproducible, non-invasive but <u>cannot</u> eval retroperitoneum or differentiate ascites + blood

vascular injury : artery has <u>triphasic</u> flow : 

; <u>dissection</u>: turbulent false lumen

<u>blunt cardiac</u> injury : echo if not stable, arrhythmia, new murmur, CHF ; look for WMA and <u>regurg</u> (AV > MV)

VSD > ASD , RA or RV rupture (tamponade, 80% die)

MCS

ECMO

<u>VV</u> : ~10 cm separation b/w cannulas, r/o cardiac etiology → may need <u>VA</u>

<u>monitoring</u> : "chattering"/ poor drainage → hypovolemia, cannula position Δ, thrombus, tamponade/ tension PTX

poor LV unloading : AV opening, SEC, LV distention, ↑MR, ↑AI loss of pulsatility → failing LV

LV filling from transpulm flow, bronchial veins, AI → may need vent

predictors of successful wean (flows < 1.5 L/min) → LVOT VTI > 10 cm, LVEF > 20-25%, peak systolic lateral mitral s' > 6 cm/s

<u>LVAD</u> : decompress LV, reduce MR, enough filling for intermittent AV ejection

<u>inflow</u> aligned w/ MV, PWD < 1.5 m/s ; high parasternal for <u>outflow</u>, CW < 1.5 m/s ; end diastolic <u>IVS</u> should neutral

<u>HM3</u> has intermittent ↓ rpm to prevent suction events ; <u>PFO</u> can cause R→L shunt and hypoxemia

<u>RV failure</u> : IVS/IAS bow leftward, ↑IVC, ↓RVOT VTI, RV dilation, ↑TR

<u>low flow</u> : hypovolemia, RV failure, tamponade, ↑afterload, inflow thrombus/kink

<u>high flow (power)</u> : pump thrombosis, vasodilation, severe AI

<u>Impella</u> : 2.5, CP (4.3 L/m), 5, LD (5 L/m, in asc. A_o) ; CI : LV thrombus, mech. AV, RV failure, tamponade (>mod AI AVA < 0.6 cm² ASD/VSD)

inflow ~3.5 cm from AV annulus ; signal tracing A_o pressure vs LV

<u>RP</u> : inflow in IVC, outflow in PA w/ fluoro ; CI : RA/RV clot, mech. TV/PV, severe TV/PV lesions

<u>IABP</u> : tip 1-2 cm distal to LSA ; CI : > mod AI, A_o dissection, severe aortic atherosclerosis

Aorta + Great Vessels

aneurysm/dissection: size, flap location, AI, LV size/fxn, effusion, vessel involvement

cystic medial degeneration: CTD (Marfans, EDS), congenital (BAV, Turners, coarctation)

atherosclerosis, inflammatory (? infectious)

criteria for surgery (elective): asc. Ao diameter ≥ 5 cm (>4.5 in Marfans), desc. ≥ 6 cm, symptoms, 2/2 trauma, ↑ >0.5 cm/yr, CSA/ht >10

CT/MRI eval whole aorta + coronaries

AI: malcoaptation due to dilated root, prolapse, dissection extends through AV, BAV

intramural hematoma (IMH): vasa vasorum rupture → hematoma extends below adventitia (no intimal tear) — crescent shape along Ao on non-con CT

penetrating aortic ulcer: plaque rupture in toward media, confined from expansion → saccular/pseudoaneurysm — rupture, hematoma

almost always desc. Ao, elderly, other atherosclerotic dz

atheroma grading: 1 (normal), 2 (intimal thickening), 3 (<5 mm), 4 (>5 mm), 5 (mobile)

inflammatory aortopathies: syphilis, giant cell, mycotic aneurysm, infected plaque

PE and pHTN

acute: >30-50% obstruction, ↑RV overload → RV failure: ↑PAP, PVR, RAP; ↓RVEF, LVEF

DVT in 30-50% PE, LE dopper >90% sens, >95% spec. in symptomatic DVT

TTE findings: clot in situ, small LA/LV (hyperdynamic), RV strain (dilation, dysfxn, IVS displaced), TR worsening V > 2.7 m/s

McConnell's sign (apex preservation), ↓TAPSE, 60/60 (TR < 60 mmHg, pulm flow accel. time < 60 ms)

pulm infarction on lung U/S (mainly dorsal lobes)

pulmonary-heart syndromes: PE, fat/gas/amniotic embolism, cor pulmonale, ARDS, RV infarct, pulm contusions

stable: if RV strain → catheter-directed tPA + heparin (submassive); if not, just heparin

unstable: moving thrombus (systemic tPA), thrombus in PA (catheter + systemic tPA + heparin), high prob. + DVT (sys. tPA)

ARDS

Berlin criteria: P/F < 300 (mild), 100-200 mod, <100 severe, bilat. infiltrates, acute onset after PNA, trauma, sepsis, aspiration, non-cardiogenic

acute cor pulmonale: acute RV dilation/dysfxn 2/2 ↑PVR (unrecruited lung, alveolar overdistention)

RVEDA/LVEDA < 0.6 (normal), 0.6-1.0 (mod. dil), >1.0 (severe dilation); TAPSE < 17 mm = abnl function

$FAC = \frac{EDA - ESA}{EDA}$ > 35% normal

normal S' > 9.5



acute cor pulmonale (ACP) risk score in ARDS: 1 point each: PNA, driving P ≥ 18 cm H_2O, P/F < 150, P_aCO_2 > 48

tx ACP: cautious fluids (small boluses/diuresis), maintain NSR, pulm dilators, vaso 0.03 u/m vasodilates

DVT/vascular access

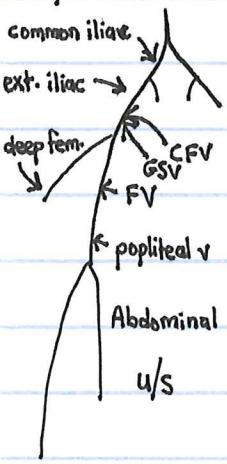

DVT incidence ~10% despite VTE PPX → on vent, pressors, CVC, trauma, ESRD, immobile, hx of VTE, surgery

look for adjacent artery, visualize saphenous vein and trifurcation, if normal then vein walls touch (abnl then artery must collapse)

vascular access: high frequency probe (superficial structures); intersection of the vessel, needle, and U/S beam

Abdominal U/S

RUQ: supine or LLD → inspiration brings GB into view : intercostal or R mid-axillary (indicator to head) subcostal (indicator to R)

cholelithiasis (hyperechoic, mobile foci, shadowing); polyps (immobile, no shadows); cholecystitis (ant wall >3 mm perichol. fluid, 10×5 cm distention, sonographic Murphy's)

CBD: >6 mm is dilated, find PV first, "exclamation sign"



renal: mid-ax line (indicator to head) → eval for anechoic hydronephrosis: mild (pelvis) mod (calyces) severe (cortical thinning)

PVRV = 1.4 × w × d · 0.75

bladder: post-void residual > 250 cc abnormal; Foley dysfxn? urinary retention? ureteral obstruction?

ascites: curvilinear probe in lower quadrants, use U/S w/ paracentesis (see epigastrics + veins)

abdom Ao: transverse (probe to R) and longitudinal (to head), bend knees, measure at celiac/SMA, just distal to SMA, just before iliac bifurcation (nl < 3 cm diameter)

95% rupture into RP, so if unstable w/ AAA → OR

Aortic valve

AS: small, concentric LVH (women > men); AI: dilated LV, eccentric hypertrophy, forward SV ↑ relative to AI severity

mean life exp 5 yrs (angina), 3 yrs (syncope), 2 yrs (HF) $DI = V_{LVOT}/V_{AV}$

AS causes: degenerative (calcified), BAV, rheumatic; aortic dimensions (PLAX, end diastole): root, STJ, sinuses, asc. Ao

grading: mild (2.6-2.9 m/s, mean <20, AVA >1.5, DI >0.5), mod (3-4 m/s, mean 20-40, AVA 1-1.5, DI 0.25-0.5)

AI causes: congenital, HTN, trauma, infn, degen., myxomatous, CVD, Ao root Δ

grading: mild (<25% jet width/LVOT, PHT >500 ms), severe (>65%, PHT <200 ms, holodiastolic flow reversal in Ao)

normally MV closes at R-wave → severe AI causes MV to close earlier (M-mode on PLAX on MV)

acute AI: ↑LVEDV/P, ↑LAP → compensatory tachy → cardiogenic shock + pulmonary edema, ↓ coronary PP

chronic AI: ↑ wall stress from ↑LVEDV → ↑LV afterload → V overload → eccentric, P overload → concentric

Mitral Regurgitation

jet direction: leaflet motion: type 1 - normal (central perforation/cleft), 2 - excessive (away prolapse/flail), 3 - restricted (typ. toward fibrosis < rheum.)

posterior flail repairable 95+% (ie, quad/triangular resection); anterior prolapse 70 (75-90%) repair

bileaflet: 80-90% prolapse repair success, ↑ SAM risk (sliding leaflet repair ↓ SAM)

restricted MR (rheumatic, radiation, lupus) → 35-55% repair, but fibrosis continues

papillary rupture: ischemic MR (rare cause) → reimplant muscle

2° (functional) MR: apical tethering of normal leaflets → from LV dilation/dysfxn

post op survival worse for 2° than 1° MR

ERO (PISA): $\frac{2\pi r^2 V_{alias}}{V_{MR,peak}}$; regurg volume = $VTI_{MR} \cdot ERO$ VC (vena contracta): largest jet width

mild MR: VC < 3 mm, ERO < 20 mm²; severe MR: VC > 7 mm, ERO > 40 mm²

indications for surgery in 1° MR: symptoms, LV dysfunction, LVID > 40 mm, AFib, rest PASP > 50 mmHg

Tricuspid and Pulmonic Valve

TV: septal and ant. leaflets in A4C and parasternal RV inflow-outflow

TR common, ↑ w/ pHTN, abnl leaflets, annular dilation (> 40 mm, > 21 mm/m²)

1° TR: Ebstein, abnl TV (carcinoid, trauma, prolapse, endocarditis), iatrogenic (radiation, drugs, PPM/ICD)

2° TR: pHTN, annular dilation, RV dz, LH dz

TR dense, triangular, early peak → HVF w/ systolic flow reversal (only blunted in mod. TR)

severe TR: E wave > 1 m/s, HVF sys. reversal, VC > 7 mm, ERO ≥ 0.4 cm²; careful w/ $4v^2$ (high $\vec{v}$) P_{RV} inaccurate

Ebstein: apical displacement of septal leaflet, atrialized RV, 50% ASD/PFO, 25% accessory pathway

TR velocity ≠ TR severity; ↑ TR velocity ∝ ↑ P_{RV} (pHTN, PS, RVOT obstruction, PE)

↓ TR velocity → ↑ RAP, severe TR, RV dysfxn

surgery: severe TR w/ symptoms refractory to meds, severe TR when having L heart surgery

mod. TR if annulus > 4 cm and having LH surgery

TS: congenital, prosthetic, rheumatic, carcinoid → thick, calcified leaflets; severe TS: MG > 5 mmHg PHT ≥ 190, TVA < 1.0 cm²

severe TR ↑ MG, PHT confounded by RV dz or PI

PV: left, right, anterior cusps → SAX, outflow, apical, subcostal views

PR: distorted/absent cusps, annular dilation → TOF repair, endocarditis, carcinoid → CFD reversal in PA

triangular diastolic flow (peak $\vec{v} \sim 2$ m/s); IVS diastolic flattening w/ ↑RA/RV size

PADP = $V^2_{max,PR}$ + RAP PASP w/ PS = RVSP − peak PV gradient

PS: prosthetic, congenital, carcinoid, Noonan (autosomal dom., HCM, short, webbed neck, CHD−PS)

echo: RVH, shifted IVS, thick cusps ; intervention if: symptoms: peak ≥ 50, MG > 30 mmHg
no " : peak ≥ 60, MG ≥ 40 mmHg

Intracardiac masses

thrombus: new Q waves, hypoperfused, ↓ size after anticoag.

papillary fibroelastoma: MCC tumor on valves

CHD in Adults

more adults than children w/ CHD

BAV: 1-2% (2-3:1 male to female), 86% R-L cusp, → ~~sgt~~ systolic doming + eccentric closure

coarctation: abdom. Ao PWD: normal:  coarctation: 

LVOT obstruction: subaortic stenosis (membrane vs. fibrous ridge), supravalvular AS

ASD: dyspnea, paradoxical embolus, atrial arrhythmia, RH dilation (L→R shunt), TR from RV dilation

secundum: central IAS, CFD to see shunt

primum: MCC CHD in Down's: deficient AV septum (abnl AV valves) a/w cleft MV or TV, VSD, LVOT obstruction

sinus venosus: SVC > IVC, a/w anomalous PV return

Scimitar syndrome: partial anomalous PV return from R lung to systemic vein (IVC)
hypoplastic R lung, cardiac structures shift right

PFO: ~30% adults, not an ASD (potential communication); agitated saline in LA in 3-6 beats

TOF: problems after repair: PI, PS, residual VSD, AI (PI most common)

VSD: membranous most common, uncommon to present as an adult